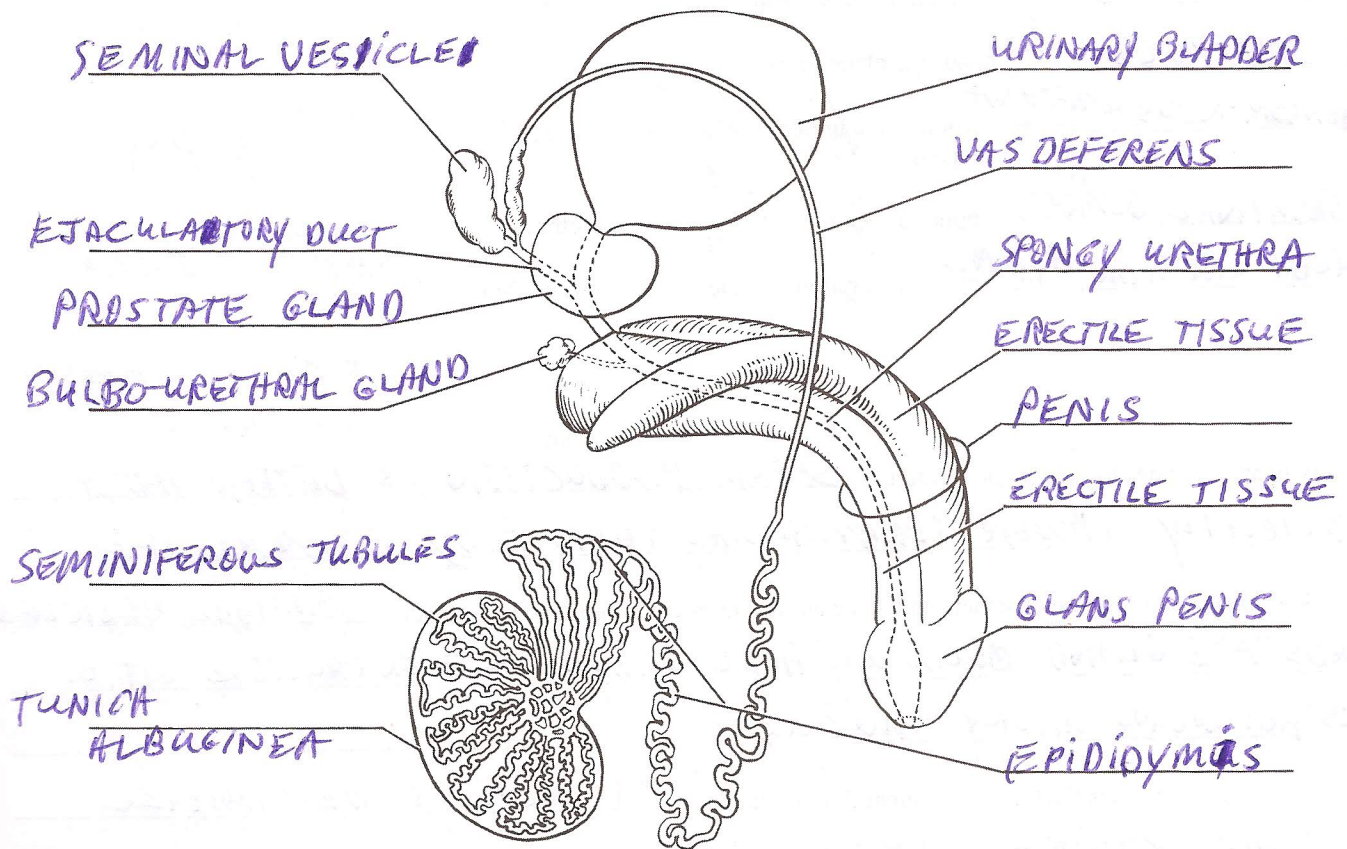


# Anatomy of the Reproductive System

## Gross Anatomy of the Human Male Reproductive System

- List the two principal functions of the testis: PRODUCE SPERM + TESTOSTERONE
- Identify all indicated structures or portions of structures on the diagrammatic view of the male reproductive system below.



- How might enlargement of the prostate interfere with urination or the man's reproductive ability?

ENLARGED PROSTATE WILL CONSTRICT THE EJACULATORY DUCT AND/OR URETHRA CAUSING PAINFUL EJACULATIONS OR PAIN URINATION.

4. Match the terms in column B to the descriptive statements in column A.


Column A	Column B
<u>PENIS</u> 1. copulatory organ/penetrating device	bulbo-urethral gland
<u>TESTIS</u> 2. produces sperm	epididymis
<u>DUCTUS DEFERENS</u> 3. duct conveying sperm to the ejaculatory duct; in the spermatic cord	glans penis
<u>PENILE URETHRA</u> 4. a urine and semen conduit	membranous urethra
<u>EPIDIDYMIS</u> 5. sperm maturation site	penile urethra
<u>SCROTUM</u> 6. location of the testis in adult males	penis
<u>PREPUCE</u> 7. hoods the glans penis	prepuce
<u>MEMBRANOUS URETHRA</u> 8. portion of the urethra between the prostate and the penis	prostate
<u>SEMINAL GLAND</u> 9. empties a secretion into the prostatic urethra	prostatic urethra
<u>BULBO-URETHRAL GLAND</u> 10. empties a secretion into the membranous urethra	seminal gland
	scrotum
	testis
	ductus deferens

5. Why are the testes located in the scrotum? SPERM PRODUCTION IS BETTER AT A SLIGHTLY LOWER TEMPERATURE THAN BODY TEMPERATURE

6. Describe the composition of semen, and name all structures contributing to its formation. SEMINAL VESICLES, PROSTATE GLAND, BULBO-URETHRAL GLAND; RICH IN FRUCTOSE, VIT. C, PROSTAGLANDINS, MILKY, MUCUS

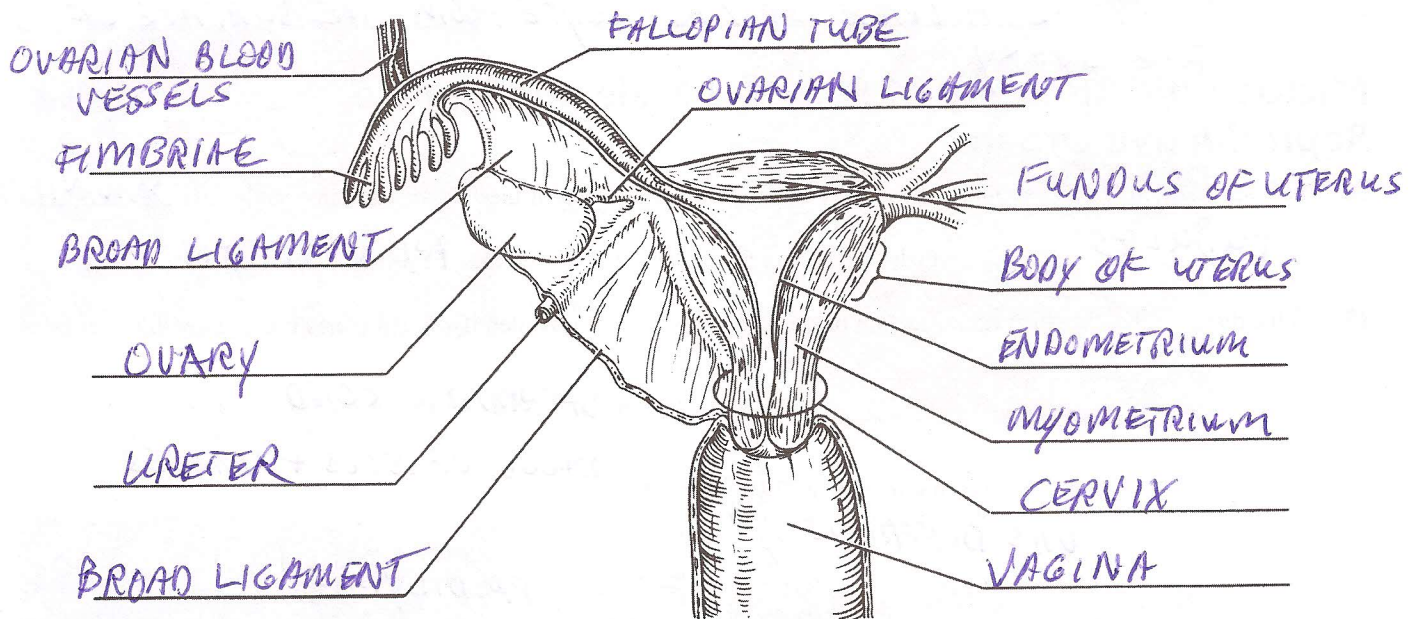
7. Of what importance is the fact that seminal fluid is alkaline? IT HELPS TO NEUTRALIZE ACIDIC VAGINAL SECRETIONS

8. Using the following terms, trace the pathway of sperm from the testes to the urethra: rete testis, epididymis, seminiferous tubule, ductus deferens.



## Gross Anatomy of the Human Female Reproductive System

9. Below is a diagram of a frontal section of a portion of the female reproductive system. Identify all indicated structures.



10. Identify the female reproductive system structures described below:

- UTERUS 1. site of fetal development  
VAGINA 2. copulatory canal  
FALLOPIAN TUBE 3. "fertilized egg" typically formed here  
CLITORIS 4. becomes erectile during sexual excitement  
FALLOPIAN TUBE 5. duct extending superolaterally from the uterus  
OVARY 6. produces eggs, estrogens, and progesterone  
FIMBRIAE 7. fingerlike ends of the uterine tube

11. Name the structures composing the external genitals, or vulva, of the female. MONS PUBIS, LABIA MAJORA,

LABIA MINORA, CLITORIS, URETHRAL + VAGINAL ORIFICES

GREATER VESTIBULAR GLANDS

12. Put the following vestibular-perineal structures in their proper order from the anterior to the posterior aspect: vaginal orifice, anus, urethral opening, and clitoris.

Anterior limit: CLITORIS → URETHRAL OPENING → VAGINAL ORIFICE → ANUS

13. Name the male structure that is homologous to the female structures named below.

labia majora SCROTUM clitoris PENIS ovaries TESTIS

14. Assume a couple has just consummated the sex act and the male's sperm have been deposited in the woman's vagina. Trace the pathway of the sperm through the female reproductive tract.

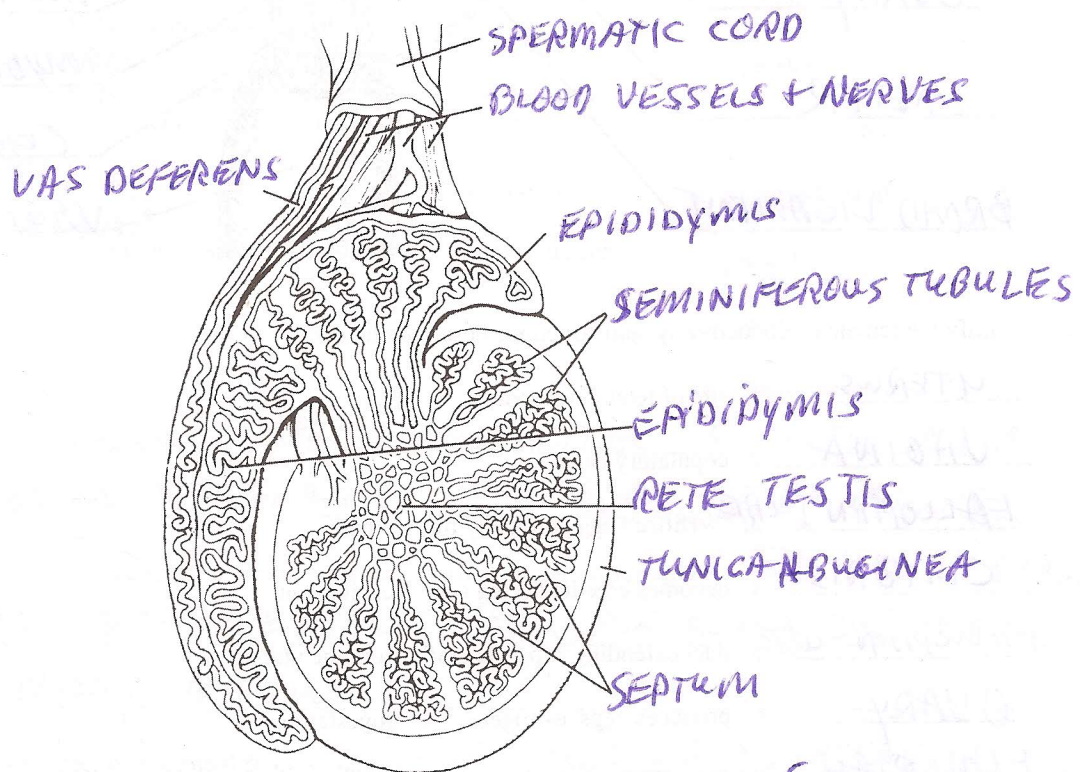
VAGINA, CERVICAL CANAL, LUMEN OF UTERUS, FALLOPIAN TUBES, INFUNDIBULUM, FIMBRIAE

15. Define ovulation: THE RELEASE OF AN OOCYTE FROM THE SURFACE OF THE OVARY

### Microscopic Anatomy of Selected Male and Female Reproductive Organs

16. The testis is divided into a number of lobes by connective tissue. Each of these lobes contains one to four SEMINIFEROUS TUBULES, which converge on a tubular region called the RETICLE TESTIS

17. On the diagram showing the sagittal section of the human testis, correctly identify all structures provided with leader lines.



18. In the female reproductive system, what is a follicle? A GROUP OF CELLS SURROUNDING AN IMMATURE OOCYTE

How are primary and vesicular follicles anatomically different? PRIMARY FOLLICLES HAVE IMMATURE OOCYTES + FOLLICULAR CELLS SURROUNDING THEM: VESICULAR FOLLICLES HAVE MATURE OOCYTES + A LARGE-FLUID FILLED REGION SURROUNDED BY FOLLICULAR CELLS

What is a corpus luteum? FOLLICULAR CELLS THAT HAVE DIFFERENTIATED TO PRODUCE PROGESTERONE AFTER THE MATURE OOCYTE HAS OVULATED

19. What hormones are produced by the corpus luteum? PROGESTERONE + SOME ESTROGEN